

# Cataract surgery in a patient with cystoid macular edema after central retinal vein occlusion: Combination with intravitreal dexamethasone implant

Florian T. A. Kretz, Gerd U. Auffarth

International Vision Correction Research Centre (IVCRC), University of Heidelberg, Department of Ophthalmology, Heidelberg, Germany

## Abstract

A 77 years old patient presented for cataract surgery. At first visit we found a cataract and hypertensive signs of the fundus. Six month later during pre-surgical examination a cystoid macular edema (CME) caused by central retinal vein occlusion (CRVO) was found. As the cataract had proceeded, we decided to perform a combined surgery with intravitreal application of a dexamethasone implant. The biometry of the first visit was used for IOL calculation. The procedure was performed without complications. Pre-surgical BCVA [logMAR] increased from 0.3 to 0.1 ten days after surgery while the central retinal thickness decreased from 586 $\mu$ m to 353 $\mu$ m with a nearly complete disappearance of the CME. Cataract surgery in patients with CME after CRVO can be combined with an intravitreal dexamethasone implant and so lead to a good visual rehabilitation. Further studies are needed to give better evidence of the effectivity and to predict the possible treatment duration.

Received June 26, 2012, accepted November 8, 2012

Key words: central retinal vein occlusion; cataract; macular edema

\*Correspondence: florian.kretz@med.uni-heidelberg.de

## Introduction

The development of a cataract is a normal process while growing old. Nearly 100% of people already have lens changes in the late 6th decade of their life. (Xu et al., 2006) As the world wide population has a higher expectancy of life, more and more people will undergo cataract surgery. Also other diseases have a higher prevalence in older populations like hypertension for example and can so lead to ocular complications, too. Hypertension itself is a widely known risk factor for the development of a central retinal vein occlusion (CRVO) that can result in a secondary cystoid macular edema with a high vision loss. For those diseases alone, the cataract or the secondary macular edema after CRVO, we have fully developed treatment options. A cataract can be dissolved by a simple cataract surgery which is the most common surgery worldwide. For the treatment of macular edemas there are several therapy options available. Therapies therefore are only the intravitreal injection of ranibizumab (Lucentis®/ Novartis) (Campochiaro et al., 2010; Chun, Heier, Topping, Duker, & Bankert, 2006; Frampton, 2012; Heier et al., 2012a; Nguyen et al., 2012) or the implantation of a dexamethasone intravitreal implant (Ozurdex®/ Allergan) (Coscas et al., 2011; Haller et al., 2010; Meyer & Schonfeld, 2011a, 2011b; Parodi, Iacono, Cascavilla, Zucchiatti, & Bandello, 2012; Winterhalter, Ruokonen, van der Velden, Pleyer, & Jousen, 2011; Yeh et al., 2012). While the treatment with laser coagulation has lost its stand, other options are the off-label use of bevacizumab and triamcinolon for intravitreal injection in the treatment of macular edemas. (Ding et al., 2011; Sonoda, Arimura, Shimura, & Sakamoto, 2011; Wu et al., 2008) Only a few studies show the effect of combined surgery with a regular cataract extraction following the intravitreal injection of triamcinolon or bevacizumab for the treatment of different types of macular edemas (Ahmadabadi, Mohammadi, Beheshtnejad, & Mirshahi, 2010; Akinci, Batman,

Ozkilic, & Altinsoy, 2009; Akinci, Muftuoglu, Altinsoy, & Ozkilic, 2011; Jonas et al., 2007), but none for the combined surgery with the treatment of a secondary CME following CRVO, nor of the combination of cataract surgery with the application of a 0.7mg intravitreal dexamethasone implant. In this case report we want to show the effectiveness and simplicity of that combination that lead to a very well visual rehabilitation for our patient.

## Case report

A 77 years old patient was transferred to our medical outpatients department for cataract surgery. At the first visitation we found a dense cataract combined with hypertonic signs of the posterior pole. We performed a biometry by using the IOLMaster V5.4 (Zeiss Meditec, Germany) and calculated the IOL power with the Holladay 1 formula. Because of personal reasons, the patient showed up six month later for another pre-surgical examination for the recommended cataract surgery. During that visit we found a secondary cystoid macular edema (CME) caused by central retinal vein occlusion (CRVO). As the cataract had proceeded, we decided to perform a combined surgery with an intravitreal application of a dexamethasone implant 0.7 mg (Ozurdex®/Allergan) (Fig.1). A monofocal IOL for in-the-bag implantation (AMO AR40e/+21.5 D) was chosen and after a regular phacoemulsification and lens implantation we performed the intravitreal dexamethasone 0.7mg implantation without any complications in full anesthesia. Pre- and post-surgical best corrected distance visual acuity (BCVA) [logMAR], intraocular pressure (IOP) and central retinal thickness (Spectralis-OCT/Heidelberg) were evaluated. Pre-surgical BCVA increased from 0.3 to 0.2 on the first post-surgical day and to 0.1 on the 10th day. From there BCVA stayed stable between 0.1 and 0.0 during follow up time of 8 month. The central retinal thickness decreased from 628 $\mu$ m to 291 $\mu$ m 12 days after surgery with a nearly complete disappearance of the macular edema and decreased to around 270  $\mu$ m where it stayed stable during follow up time. (Fig. 1) IOP stayed in a normotone region during whole follow up time.

## Discussion

As people become older these days, more cataract cases will show up in the surgical practice. The older people become, the more the risk factors increase for co morbidities. Hypertension is a known disease for the elderly and can result in ocular complications just like central retinal vein occlusion. (Rehak & Wiedemann, 2010; Thapa, Paudyal, & Bernstein, 2010) Hereby a developed cataract can influence the diagnostics as it has a high influence towards the visual acuity and also limits possible retinal thickness measurements. (Kim et al., 2012) It is also frustrating for our patients that a measured decrease of a secondary CME after CRVO is not followed by an increase of the visual acuity as the cataract is the limiting factor. A few studies have already proven the effectiveness of the combination of cataract surgery and intravitreal injection of bevacizumab or triamcinolon in secondary CME. (Ahmadabadi et al., 2010; Akinci et al., 2009; Akinci et al., 2011; Jonas et al., 2007) But that is still therapy in off-label use. As we also know that the effect of bevacizumab,

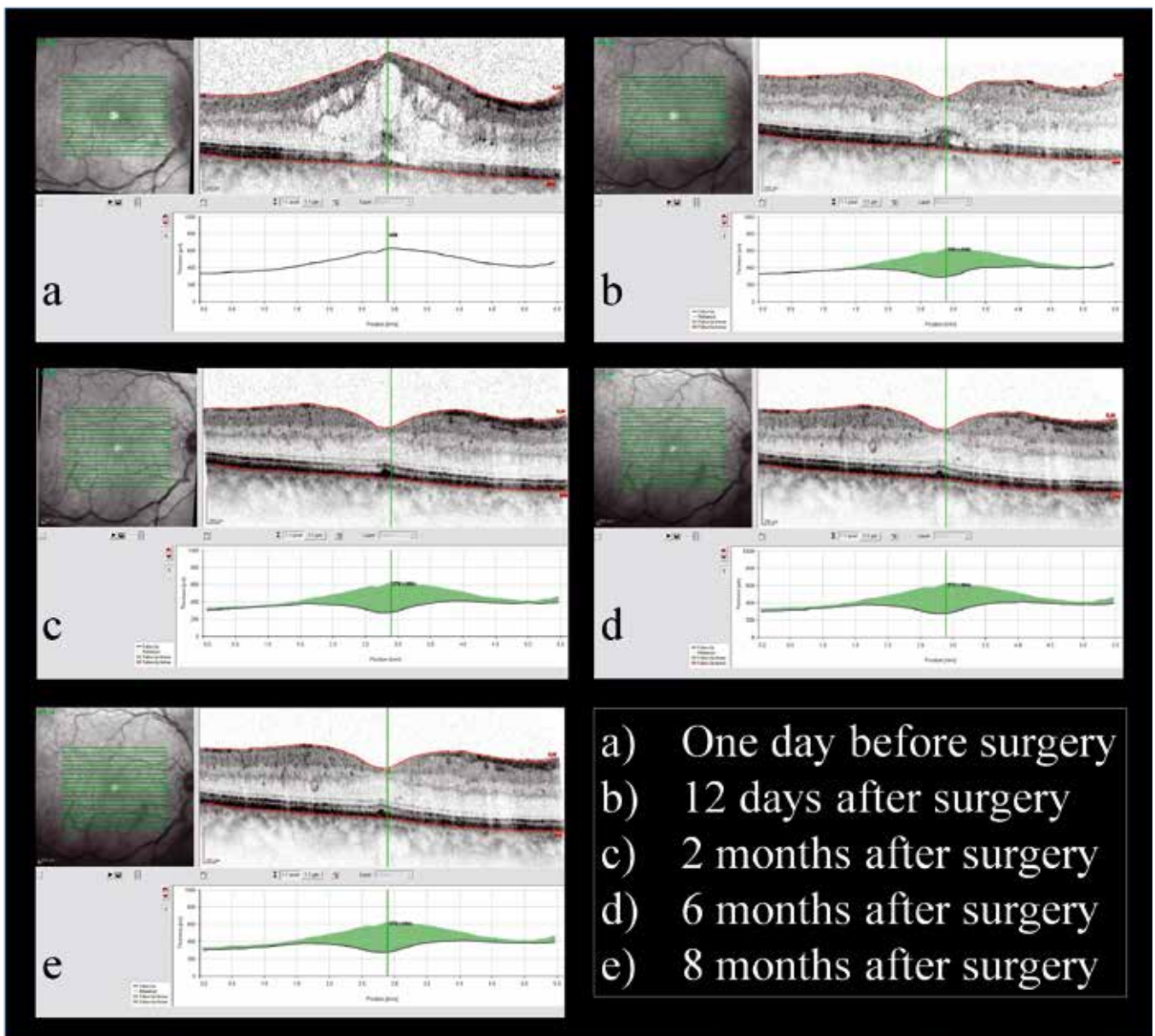


Figure 1. Macular thickness measurement during follow up time

ranibizumab or triamcinolon only lasts for a couple of weeks (Campochiaro et al., 2010; Chun et al., 2006; Ding et al., 2011; Frampton, 2012; Heier et al., 2012b; Nguyen et al., 2012; Sonoda et al., 2011; Wu et al., 2008), newer medications like 0.7 mg intravitreal dexamethason implants (Ozurdex®/Allergan) have shown a far longer lasting effect for the treatment of secondary CME after CRVO (Coscas et al., 2011; Haller et al., 2010; Meyer & Schonfeld, 2011b; Parodi et al., 2012; Winterhalter et al., 2011; Yeh et al., 2012) or CME after cataract surgery (Meyer & Schonfeld, 2011a), so it can be guessed that their effect should also last longer in direct combination with cataract surgery and so decrease the risk of endophthalmitis (McCannel, 2011; Moshfeghi, 2011) as less injections are needed. With a better visual rehabilitation by giving clear optical medias, the satisfaction for our patients and with it their trust in our treatments should increase, as a faster visual rehabilitation with a longer lasting effect is given by the combination of cataract surgery with an 0.7mg intravitreal dexamethason implant (Ozurdex®/Allergan). Also the intraocular steroid effect should lower post-surgical inflam-

mation and prevent an Irvine-Guess syndrome, as treated before it appears. (Meyer & Schonfeld, 2011a) Still, further studies will be needed to give a better evidence of the effectiveness of these combined procedures and the prediction of the possible treatment duration.

#### References

- Ahmadabadi, H. F., Mohammadi, M., Beheshtnejad, H., & Mirshahi, A. (2010). Effect of intravitreal triamcinolone acetonide injection on central macular thickness in diabetic patients having phacoemulsification. [Randomized Controlled Trial]. *Journal of cataract and refractive surgery*, 36(6), 917-922. doi: 10.1016/j.jcrs.2009.12.030
- Akinci, A., Batman, C., Ozkiloglu, E., & Altinsoy, A. (2009). Phacoemulsification with intravitreal bevacizumab injection in diabetic patients with macular edema and cataract. *Retina*, 29(10), 1432-1435. doi: 10.1097/IAE.0b013e3181b77422
- Akinci, A., Muftuoglu, O., Altinsoy, A., & Ozkiloglu, E. (2011). Phacoemulsification with intravitreal bevacizumab and triamcinolone acetonide injection in diabetic patients with clinically significant macular edema and cataract. *Retina*, 31(4), 755-758. doi: 10.1097/IAE.0b013e3182006da1

- Campochiaro, P. A., Heier, J. S., Feiner, L., Gray, S., Saroj, N., Rundle, A. C., Rubio, R. G. (2010). Ranibizumab for macular edema following branch retinal vein occlusion: six-month primary end point results of a phase III study. [Clinical Trial, Phase III Comparative Study Multicenter Study Randomized Controlled Trial Research Support, Non-U.S. Gov't]. *Ophthalmology*, 117(6), 1102-1112 e1101. doi: 10.1016/j.ophtha.2010.02.021
- Chun, D. W., Heier, J. S., Topping, T. M., Duker, J. S., & Bankert, J. M. (2006). A pilot study of multiple intravitreal injections of ranibizumab in patients with center-involving clinically significant diabetic macular edema. [Case Reports Research Support, Non-U.S. Gov't]. *Ophthalmology*, 113(10), 1706-1712. doi: 10.1016/j.ophtha.2006.04.033
- Coscas, G., Coscas, F., Zucchiatti, I., Glacet-Bernard, A., Soubrane, G., & Souied, E. (2011). SD-OCT pattern of retinal venous occlusion with cystoid macular edema treated with Ozurdex(R). [Case Reports]. *European journal of ophthalmology*, 21(5), 631-636. doi: 10.5301/EJO.2011.7428
- Ding, X., Li, J., Hu, X., Yu, S., Pan, J., & Tang, S. (2011). Prospective study of intravitreal triamcinolone acetone versus bevacizumab for macular edema secondary to central retinal vein occlusion. [Comparative Study Randomized Controlled Trial Research Support, Non-U.S. Gov't]. *Retina*, 31(5), 838-845. doi: 10.1097/IAE.0b013e3181f4420d
- Frampton, J. E. (2012). Ranibizumab: in diabetic macular oedema. *Drugs*, 72(4), 509-523. doi: 10.2165/11208410-000000000-00000
- Haller, J. A., Bandello, F., Belfort, R., Jr., Blumenkranz, M. S., Gillies, M., Heier, J., Whitcup, S. M. (2010). Randomized, sham-controlled trial of dexamethasone intravitreal implant in patients with macular edema due to retinal vein occlusion. [Multicenter Study Randomized Controlled Trial]. *Ophthalmology*, 117(6), 1134-1146 e1133. doi: 10.1016/j.ophtha.2010.03.032
- Heier, J. S., Campochiaro, P. A., Yau, L., Li, Z., Saroj, N., Rubio, R. G., & Lai, P. (2012a). Ranibizumab for Macular Edema Due to Retinal Vein Occlusions Long-term Follow-up in the HORIZON Trial. *Ophthalmology*. doi: 10.1016/j.ophtha.2011.12.005
- Heier, J. S., Campochiaro, P. A., Yau, L., Li, Z., Saroj, N., Rubio, R. G., & Lai, P. (2012b). Ranibizumab for macular edema due to retinal vein occlusions: long-term follow-up in the HORIZON trial. [Multicenter Study Randomized Controlled Trial Research Support, Non-U.S. Gov't]. *Ophthalmology*, 119(4), 802-809. doi: 10.1016/j.ophtha.2011.12.005
- Jonas, J. B., Spandau, U. H., Schlichtenbrede, F., Libondi, T., Vossmerbaeumer, U., & von Baltz, S. (2007). Intravitreal bevacizumab combined with cataract surgery for treatment of exudative macular degeneration. *J Ocul Pharmacol Ther*, 23(6), 599-600. doi: 10.1089/jop.2007.0050
- Kim, N. R., Lee, H., Lee, E. S., Kim, J. H., Hong, S., Je Seong, G., & Kim, C. Y. (2012). Influence of cataract on time domain and spectral domain optical coherence tomography retinal nerve fiber layer measurements. *J Glaucoma*, 21(2), 116-122. doi: 10.1097/IJG.0b013e31820277da
- McCannel, C. A. (2011). Meta-analysis of endophthalmitis after intravitreal injection of anti-vascular endothelial growth factor agents: causative organisms and possible prevention strategies. [Meta-Analysis Research Support, Non-U.S. Gov't]. *Retina*, 31(4), 654-661. doi: 10.1097/IAE.0b013e31820a67e4
- Meyer, L. M., & Schonfeld, C. L. (2011a). Cystoid Macular Edema after Complicated Cataract Surgery Resolved by an Intravitreal Dexamethasone 0.7-mg Implant. *Case Report Ophthalmol*, 2(3), 319-322. doi: 10.1159/000332424
- Meyer, L. M., & Schonfeld, C. L. (2011b). Fast Resolution of Recurrent Pronounced Macular Edema following Intravitreal Injection of Dexamethasone 0.7 mg. *Case Report Ophthalmol*, 2(2), 246-250. doi: 10.1159/000330665
- Moshfeghi, A. A. (2011). Endophthalmitis following intravitreal anti-vascular endothelial growth factor injections for neovascular age-related macular degeneration. [Research Support, Non-U.S. Gov't Review]. *Semin Ophthalmol*, 26(3), 139-148. doi: 10.3109/08820538.2011.570847
- Nguyen, Q. D., Brown, D. M., Marcus, D. M., Boyer, D. S., Patel, S., Feiner, L., Ehrlich, J. S. (2012). Ranibizumab for diabetic macular edema: results from 2 phase III randomized trials: RISE and RIDE. [Clinical Trial, Phase III Multicenter Study Randomized Controlled Trial Research Support, Non-U.S. Gov't]. *Ophthalmology*, 119(4), 789-801. doi: 10.1016/j.ophtha.2011.12.039
- Parodi, M. B., Iacono, P., Cascavilla, M., Zucchiatti, I., & Bandello, F. (2012). Compassionate use of dexamethasone implant for the treatment of macular edema secondary to central retinal vein occlusion in a clinical setting. [Letter]. *Acta Ophthalmol*, 90(4), e322-323. doi: 10.1111/j.1755-3768.2011.02238.x
- Rehak, M., & Wiedemann, P. (2010). Retinal vein thrombosis: pathogenesis and management. [Review]. *J Thromb Haemost*, 8(9), 1886-1894. doi: 10.1111/j.1538-7836.2010.03909.x
- Sonoda, Y., Arimura, N., Shimura, M., & Sakamoto, T. (2011). Early change of central macular thickness after intravitreal triamcinolone or bevacizumab in diabetic macular edema or retinal vein occlusion. [Comparative Study Research Support, Non-U.S. Gov't]. *Retina*, 31(2), 290-297. doi: 10.1097/IAE.0b013e3181eef070
- Thapa, R., Paudyal, G., & Bernstein, P. S. (2010). Demographic characteristics, patterns and risk factors for retinal vein occlusion in Nepal: a hospital-based case-control study. [Research Support, Non-U.S. Gov't]. *Clinical & experimental ophthalmology*, 38(6), 583-590. doi: 10.1111/j.1442-9071.2010.02295.x
- Winterhalter, S., Ruokonen, P., van der Velden, K. H., Pleyer, U., & Jousen, A. M. (2011). [Intravitreal implants: drug carriers and carriers of hope?]. [Comparative Study Review]. *Der Ophthalmologe : Zeitschrift der Deutschen Ophthalmologischen Gesellschaft*, 108(3), 222-229. doi: 10.1007/s00347-010-2264-y
- Wu, L., Arevalo, J. F., Roca, J. A., Maia, M., Berrocal, M. H., Rodriguez, F. J., . . . Cardillo, J. (2008). Comparison of two doses of intravitreal bevacizumab (Avastin) for treatment of macular edema secondary to branch retinal vein occlusion: results from the Pan-American Collaborative Retina Study Group at 6 months of follow-up. [Comparative Study Multicenter Study]. *Retina*, 28(2), 212-219. doi: 10.1097/IAE.0b013e3181619bee
- Xu, L., Cui, T., Zhang, S., Sun, B., Zheng, Y., Hu, A., Jonas, J. B. (2006). Prevalence and risk factors of lens opacities in urban and rural Chinese in Beijing. *Ophthalmology*, 113(5), 747-755. doi: 10.1016/j.ophtha.2006.01.026
- Yeh, W. S., Haller, J. A., Lanzetta, P., Kuppermann, B. D., Wong, T. Y., Mitchell, P., Kowalski, J. W. (2012). Effect of the duration of macular edema on clinical outcomes in retinal vein occlusion treated with dexamethasone intravitreal implant. [Clinical Trial, Phase III Multicenter Study Randomized Controlled Trial Research Support, Non-U.S. Gov't]. *Ophthalmology*, 119(6), 1190-1198. doi: 10.1016/j.ophtha.2011.12.028

## **Kataraktkirurgi hos en pasient med cystoid makulaødem etter sentral retinal veneokklusjon: Kombinasjon med intravitreal dexamet- hasone implantat**

### **Sammendrag**

En 77 år gammel pasient presenteres for kataraktkirurgi. Ved første besøk ble det funnet katarakt og hypertensive tegn på fundus. Seks måneder senere under pre-kirurgisk undersøkelse ble det funnet cystoid makulaødem (CME) forårsaket av sentrale retinal veneokklusjon (CRVO). Siden katarakt hadde utviklet seg, besluttet vi å utføre en kombinert operasjon med intravitreal bruk av en dexamethason implantat. Biometriske målinger fra første besøk ble brukt for beregning av intra okulær linse (IOL). Prosedyren ble utført uten komplikasjoner. Pre-kirurgisk beste-korrigerte visus [logMAR] økt fra 0,3 til 0,1 ti dager etter operasjonen mens den sentrale retinal tykkelse redusert fra 586µm til 353µm med nesten fullstendig frafall av CME. Katarakt kirurgi hos pasienter med CME etter CRVO kan kombineres med en intravitreal dexamethason implantat og føre til god visuell rehabilitering. Videre studier er nødvendig for å kunne validere effektiviteten og å forutsi mulige behandlingsvarighet.

*Mottatt 26. juni 2012, akseptert 8. november 2012*

*Nøkkelord: sentral retinal veneokklusjon, katarakt, makulaødem*

*\*Korrespondanse: florian.kretz@med.uni-heidelberg.de*