

Refitting a patient with pellucid marginal degeneration from a corneal rigid gas permeable lens to scleral lens

Eilin Lundanes and Jörgen Gustafsson

National Centre for Optics, Vision and Eye Care; Department of Optometry, Radiography and Lighting Design. Faculty of Health and Social Sciences, University of South-Eastern Norway, Kongsberg, Norway.

Received October 14, 2019, accepted June 16, 2020.

Correspondence: eilin.lundanes@usn.no

Abstract

This case report describes a 66 years old male patient with pellucid marginal degeneration (PMD). The patient had fallen out of a regular follow-up scheme and presented with a poorly fitting corneal rigid lens that he had worn for almost five years. Correction had failed to improve vision in the left eye, so the patient wears a contact lens in his right eye only. Scleral lenses vault over the cornea, the tear layer between the lens and the cornea masks corneal irregularities and are a good correction option for corneal ectasias. This patient was fitted with an Onefit scleral lens that provided good visual acuity and comfort. Lens handling was no obstacle to this patient. A heart surgery postponed the first follow-up examination. Follow-up examination 8 months after the refit resulted in no changes of lens parameters as the fitting was still acceptable and the patient was happy. Attention to the inferior limbal clearance will be the focus at the next follow-up in 6 months' time.

Keywords: *Pellucid marginal degeneration, corneal rigid lens, corneal irregularities, scleral lens*

Sammendrag

Denne kasus rapporten beskriver en 66 år gammel mannlig pasient med pellucid marginal degenerasjon (PMD). Pasienten hadde ikke hatt jevnlig rutinekontroller, og han ankom klinikken med en fem år gammel formstabil korneal linse som passet svært dårlig. Kontaktlinse bæres kun på pasientens høyre øye, da venstre øye ikke oppnår funksjonsforbedring med korreksjon. Sklerallinser hvelver over kornea, og tårelinsen mellom linsen og kornea maskerer korneale irregulæriteter. Det gjør at denne typen linser er et godt alternativ til korreksjon av korneale ectasier. Pasienten ble tilpasset med en Onefit sklerallinse som ga god visus og komfort. Håndtering av linsen var ingen utfordring for pasienten. En hjerteoperasjon utsatte første oppfølgingstid. Oppfølgingstiden 8 måneder etter tilpassing viste akseptabel linsetilpassing og fornøyd pasient, og det ble ikke gjort noen endring av linseparametere. Neste etterkontroll foretas om 6 måneder, med spesielt fokus på tilpassingen over limbus.

Nøkkelord: *Pellucid marginal degenerasjon, korneal ektasi, retilpassing, korneal linse, sclerallinse*

Background

Pellucid marginal degeneration (PMD) is a rare bilateral, asymmetric, non-inflammatory corneal ectasia that most commonly occurs in the inferior part of the cornea. A narrow band of corneal thinning is usually present in areas from around 4 o'clock to 8 o'clock, with 1-2 mm of unaffected cornea between the thinning and limbus (Martinez-Abad & Pinero, 2019). Central corneal thickness is normal, and an anterior displacement of the cornea occurs directly above the band of thinning. The vertical meridian above the area of thinning is flat; hence, irregular "against-the-rule" astigmatism is usually present. These

corneal changes result in a classical "crab-claw" topography map, also referred to as "kissing doves" or "butterfly" patterns (Jinabhai et al., 2011). Literature suggests a slightly higher incidence in men, but shows no ethnical or geographical predisposition (Jinabhai et al., 2011), nor familial inheritance (Martinez-Abad & Pinero, 2019). Systemic diseases associated with eye rubbing and progressive connective tissue diseases might be associated with PMD, this is yet to be confirmed (Martinez-Abad & Pinero, 2019).

PMD can easily be confused with other bilateral corneal ectatic disorders, such as keratoconus and keratoglobus. The etiology of these ectasias is not fully understood. Possibly these are not three different diseases, but rather different clinical presentations of the same underlying disease (Martinez-Abad & Pinero, 2019). Keratoconus is the most common corneal ectasia. It usually occurs earlier in life (puberty) and progresses more rapidly than PMD. With the cone situated away from the corneal centre and a topographic "crab-claw" pattern, inferior keratoconus resembles PMD (Koc et al., 2018). However, in all clinical cases of keratoconus, Fleisher ring and Vogt's striae are present. In moderate and severe cases apical corneal scarring, Rizutti's phenomenon and Munson's sign also are present in keratoconus. All these signs are absent in PMD (Jinabhai et al., 2011).

Spectacles and soft contact lenses work well in early stages of PMD. As the condition progresses, and irregular astigmatism and corneal irregularity occur, rigid gas permeable (RGP) contact lenses are usually required. Hybrid contact lenses, piggyback, large-diameter RGP, bitoric RGP or reverse-geometry RGP might be needed to avoid excessive inferior edge stand-off (Asena & Altnörs, 2016; Jinabhai et al., 2011; Rathi et al., 2016). Several authors have reported successful fitting of scleral lenses for patients with advanced PMD (Asena & Altnörs, 2016; Biswas et al., 2000; Ozek et al., 2018; Pullum & Buckley, 1997; Rathi et al., 2016). Scleral lenses vault over the entire cornea and rest on the sclera. The tear reservoir under the lens masks the corneal irregularity and increases visual acuity and comfort (Otchere et al., 2017). A variety of terminology has been in use to describe various modalities of scleral lenses. Terms like mini-scleral and full scleral lenses, differentiate lenses with a total diameter up to 6 mm larger than horizontal visible iris diameter (HVID) from lenses with larger total diameters. In "An official guide to scleral lens terminology" published in Contact Lens and Anterior Eye recently, Michaud et al. (2019) suggest avoiding this terminology. All lenses that vault entirely over cornea and limbus are to be called scleral lenses (Michaud et al., 2019).

The fitting of scleral lenses on corneal ectasias has grown rapidly over the past few years due to improved lens designs, development of highly oxygen permeable lens materials, and increased awareness and acceptance by ophthalmologists around the world (Asena & Altnörs, 2016; Otchere et al., 2017). There are potential contraindications to consider upon fitting scleral lenses. Fadel and Kramer (2019) have recently done a literature review, resulting in the provision of guidelines on how to proceed caution in certain conditions. According to the authors, potential contraindications for scleral lens wear are significant corneal endothelial abnormalities, glaucoma or following glaucoma therapy, and overnight wear.

The approach to fitting scleral lenses varies between manufacturers, and it is useful to read the fitting guide for the specific lens before fitting. In the case presented, the fitting guide and trial set chosen were for Onefit designed by Blanchard Lab

Canada, manufactured by Multilens, Sweden (Blanchard Contact Lenses, 2018).

Case presentation

This case presents a male born in 1952, who came to our clinic in August 2018, referred by a colleague. For several reasons he was lost to follow-up for almost five years. The patient was diagnosed with bilateral PMD in 2012 and wore spectacles and soft contact lenses successfully until he was about 50 years of age. Eventually he was fitted with corneal rigid lenses in 2013. Correction failed to improve vision in the left eye, and lens wear in this eye was discontinued.

The patient presented with a Rose K2 IC contact lens (Menicon Co, Nagoya, Japan) received in February 2014. Wearing time was approximately 15 hours a day. Without this lens, the patient felt he was blind. He wore reading spectacles over the contact lens, but he still noticed shadows on letters when reading. Despite a very old contact lens, the patient did not experience ocular redness, or discomfort, or problems with the lens.

The patient came in wearing his Rose K2 IC lens. Initially, visual acuity, over-refraction and assessment of the lens fitting with the slit-lamp were performed. After lens removal, corneal topography with Medmont M700 (Medmont International, Nunawading, Australia) and assessment of the anterior segment using a slit lamp with and without fluorescein were done. The fitting of a scleral lens to the right eye only was completed according to the Onefit fitting guide. Assessment of the fit was repeated after one hour of wear, and over-refraction was done. In addition to the procedures already mentioned, anterior segment OCT with Zeiss Cirrus (Zeiss MedTec AG, Oberkochen, Germany) was used for lens assessment upon follow-up.

Results

Preliminary tests

Assessment of the habitual contact lens fit using the slit lamp and fluorescein: The lens decentered inferiorly over limbus with no visible movement. The inferior lens edge was stuck in the inferior conjunctiva. The fitting was flat centrally, with a broad edge lift nasally, temporally and superiorly. Table 1 shows preliminary measurements and results of examination of the anterior segment after lens removal using the slit-lamp and Efron grading scale.

Table 1: Results of preliminary tests.

Uncorrected distance visual acuity (VA)	1.4 logMAR
Habitual correction (Rose K2) IC	Base curve 6.55 mm Diameter 11.8 mm Edge Incline +1.5 Power -6.50 D
Habitual distance VA	0.36 logMAR
Over-refraction	-1.00 DS, 0.1 logMAR
Lids	No blepharitis or Meibomian gland dysfunction
Bulbar redness	E 2.0 (in all quadrants)
Limbal redness	E 1.0
Neovascularization	E 2.0 at 2-4 o'clock and 7-8 o'clock. Ghost vessels at 10-2 o'clock.
Cornea	Visible thickness irregularities, with a band of thinning inferiorly. Clear cornea. Polymegathism: E 1.5
With fluorescein	No corneal staining. Conjunctival staining in the area where the edge of the habitual lens had been sitting.

Topography: Figure 1a shows the axial topography map of the

right eye performed with Medmont M700 (directly after removal of the Rose K lens). Four topography measurements showed repeatable results. The topography confirms an irregular cornea with flatter curvatures superiorly and the steeper curvatures inferiorly, and the surface indexes confirm large irregularities.

Keratometry readings in diopters: 45.91 @ 56° / 55.06 @ 146°
Keratometry readings in millimetres: 7.35 @ 56° / 6.24 @ 146°
The elevation difference between the highest and the lowest point of the cornea was just over 400 μm, seen in Figure 1b.

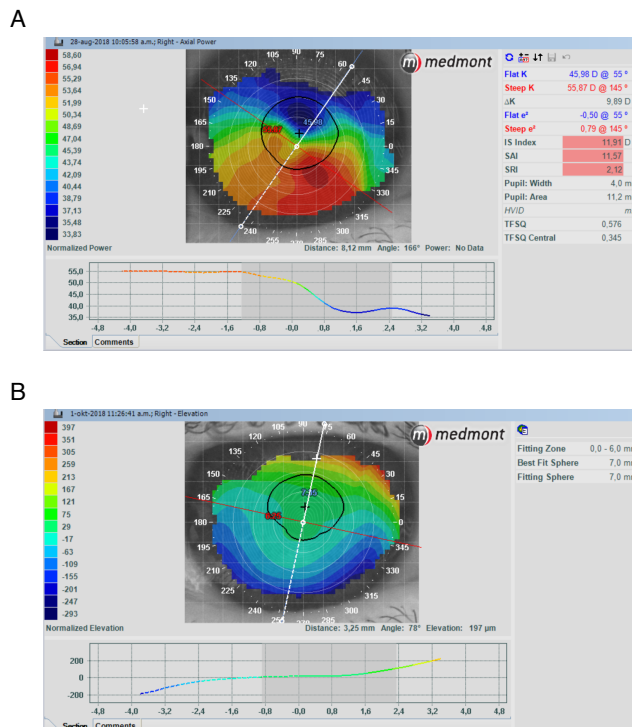


Figure 1: Corneal Topographic plot directly after lens removal of the corneal rigid lens RE.

Scleral lens fitting

We used a trial lens set of Onefit with total diameter of 14.9mm. The fitting guide recommends base curve selection to be equivalent to the flattest K-reading. The trial lens parameters are shown in Table 2, and Table 3 shows results one hour after insertion.

Table 2: Onefit trial lens parameters.

Base curve	7.30 mm
Diameter	14.9 mm
Edge	Standard
Power	-4.00 D

Table 3: Assessment of lens fit one hour after insertion.

Distance VA	0.1 logMAR
Over-refraction	+0.50 DS, no change in VA
Near VA (with add +2.00)	0.1 logMAR
Central clearance over the pupil	≈ 300 μm
Clearance inferiorly, over the cone	≈ 100 μm

The limbal clearance seemed sufficient, and the edge and edge lift were good, with no sign of blanching or impingement. The fit was considered acceptable the contact lens shown in Table 4 was ordered.

Table 4: *Onefit lens parameters ordered for patient.*

Onefit scleral lens in material	Boston XO (blue handling colour)
Base curve	7.30 mm
Diameter	14.9 mm
Edge	Standard
Power	-3.50 D

When the lens arrived, the patient came in to the clinic to learn proper lens handling and care. He had no trouble inserting the lens using an insertion cup, nor removing the lens using a regular lens remover for rigid gas permeable contact lenses. The patient was instructed to rub the lens in a standard multipurpose solution for rigid gas-permeable lens materials for 20 seconds, rinse the lens in the same solution and fill the lens case with the solution prior to placing the lens into the lens case for disinfection overnight. For lens insertion, the patient was instructed to fill the lens with unpreserved single-dose saline.

Follow-up examination

Due to a heart surgery, the first follow-up examination followed 8 months after re-fitting. During this time leaning forward to insert the lens had been impossible, and the patient had only started wearing the scleral lens approximately 3 weeks prior to the follow-up examination. The patient reported excellent comfort and vision with the scleral lens, with no complaints. On the day of follow-up the lens had been in the eye for approximately 7 hours. Acuity results are shown in Table 5.

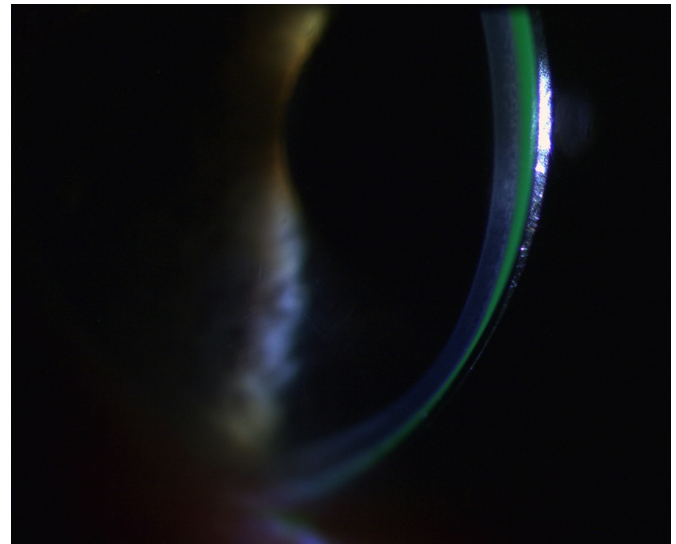
Table 5: *Assessment of lens fit approximately 7 hours after insertion.*

VA with scleral lens	0.3 logMAR
Over-refraction	-1.00 DS, 0.1 logMAR

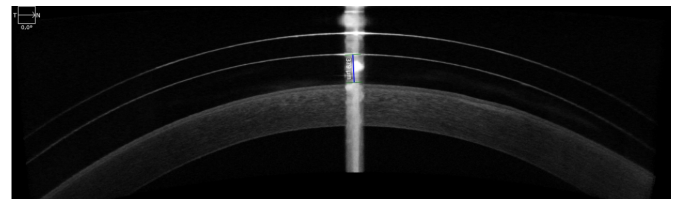
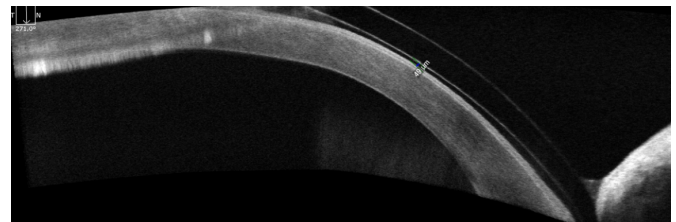
Figure 2 shows excellent lens centration and overall lens diameter. The lens extends a little more than 1.25 mm outside of limbus, which corresponds with the fitting guide recommendations. The landing zone and edge (Figure 2) align well with the sclera with no signs of impingement or blanching, nor does the lens move or allow air bubbles to enter under the edge.

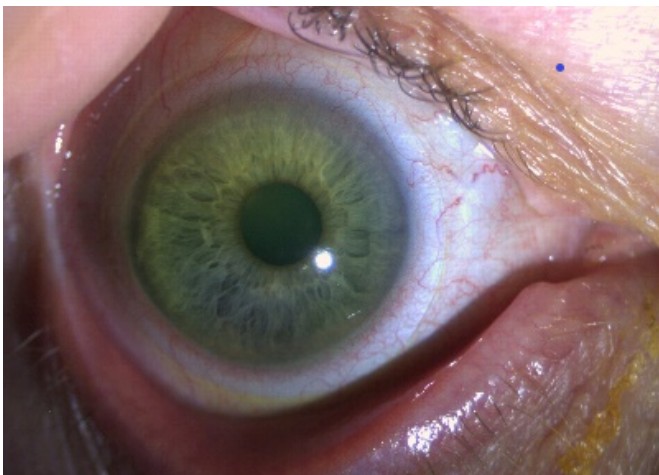Figure 2: *Lens fit in white light showed excellent centration, good overall diameter and well-fitting edge.*

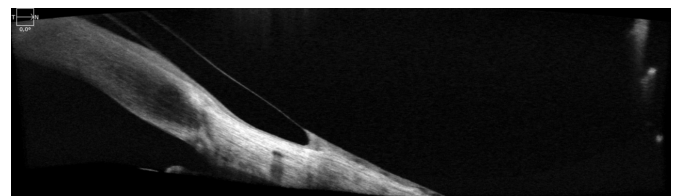
Figure 3 shows the assessment of the apical clearance using the slit lamp with white light and fluorescein in the lens bowl. Central clearance is approximately 350 μm at centre of the pupil. The clearance increases superiorly. Inferiorly, at the point where the cornea is bulging out, the corneal clearance is approximately 50 μm .

Figure 3: *Scleral lens fit seen with an optic section. Note the relatively high central clearance and the minimal inferior clearance over the highest point of the cornea.*

Anterior segment OCT (with Zeiss Cirrus) confirms these results. The OCT image of central clearance (see Figure 4) indicates a central clearance of 379 μm . Figure 5 shows a clearance of 49 μm at the apex of the cone.

Figure 4: *OCT central clearance: 379 μm .*Figure 5: *OCT clearance at the cone: 49 μm .*

The anterior segment was mainly unchanged from the initial fit, but with less bulbar redness than at the initial visit (E1.0 vs E2.0). Superficial corneal staining close to the inferior limbus from 5 to 7 o'clock, indicates a slight lens touch in this area. This corresponds with the OCT picture in Figure 6.

Figure 6: *OCT the edge sinks nicely into the conjunctiva without compression of structures. The lens seems to touch the limbal area slightly in this section.*

Discussion

This case describes a patient diagnosed with PMD several years ago, who had been wearing a Rose K2 IC large diameter RGP contact lens for several years. The patient presented with a 4

year old lens that he was happy with, except for some shadowing on letters when reading. Examination revealed an unacceptable lens fit. The excessive lens decentration resulted in a lens that was stuck in the inferior conjunctiva. This was probably the reason for conjunctival staining in this area, the bulbar redness, and the excessive edge lift in the three other quadrants. This is the opposite of what literature usually reports as a challenge with corneal RGP lenses on advanced PMD patients. Excessive inferior edge stand-off is more common (Asena & Altnörs, 2016; Jinabhai et al., 2011; Rathi et al., 2016). The inferior position of apex of cornea might be one of the reasons for the decentration. It is also likely that the lens parameters had changed with time, as RGP materials tend to deteriorate. Lens thickness reduces with time, making the lens subject to warpage. Lens binding is also common with old lenses (Efron, 2018). Refitting with a new Rose K2 lens or another corneal RGP contact lens designed for irregular corneas could have been an option for this patient. Two aspects lead to the choice of a scleral lens. Firstly, lens decentration is easier to overcome with a larger lens as opposed to a smaller lens. Secondly, topography showed a corneal elevation difference of approximately 400 μm . This would increase the risk of a small lens rocking on the corneal apex. Management of corneal height differences is easier with a scleral lens as the lens vaults over the entire cornea. As several authors have reported successful fitting of scleral lenses for patients with advanced PMD (Biswas et al., 2000; Ozek et al., 2018; Pullum & Buckley, 1997; Rathi et al., 2016), we decided to try refitting the patient. There are several scleral lens designs available, and we decided on Onefit as the trial set was already available and familiar to the clinicians.

The fitting procedure was done by following the Onefit fitting guide, apart from selection of the total diameter. The fitting guide recommends selecting the total diameter from the patient's HVID (Blanchard Contact Lenses, 2018). HVID was not measured in this case, and the trial set available only contained lenses with diameter 14.9 mm. However, this diameter was perfect. Upon insertion, the central clearance was large, but these kinds of lenses will recess during the day. During a full day of wear, a recess of 100 μm is expected (Blanchard Contact Lenses, 2018). The fitting guide recommends assessing the lens fit at application, after 30 minutes, and after 4 hours of lens wear (Blanchard Contact Lenses, 2018). During the fitting process in our case, the fit was reassessed after 1 hour only. The time needed for a scleral lens to settle is highly individual, and the average loss of central corneal clearance after one hour was $34 \pm 48 \mu\text{m}$ (Otchere et al., 2017). With this in mind, our case of 100 μm clearance of the cone might suggest that the clearance was on the small side. However, the follow-up examinations were performed in the afternoon, several hours after lens insertion, and as shown, the lens did not touch the highest point of the cornea. The clearance in the central and superior part of cornea was a little larger than recommended. With irregular corneas there will be a wide variation in clearance across the cornea (Walker et al., 2016), as seen in this case.

Limbal clearance is another important factor to consider in scleral lens fitting. Extensive clearance reduces the Dk/t , which increases the risk of hypoxia. On the other hand, touch in this area should be avoided, as it may affect the limbal stem cells (Walker et al., 2016). A limbal clearance of 100 μm is often striven for (van der Worp, 2015), but the Onefit fitting guide recommends to keep it as minimal as possible without touch. Fluorescein is not visible when the clearance is less than 25 μm , but staining in the limbal area is an indication of touch (Blanchard Contact Lenses, 2018). In addition to the staining found along the inferior part of the limbus, OCT confirmed slight limbal touch. This might be dealt with in two ways; either order lenses with "Extra limbal clearance", which will increase the

limbal clearance by 50 μm without affecting the lens behavior on the eye, or increase the total diameter of the lens (Blanchard Contact Lenses, 2018). If the lens fits well elsewhere, Walker et al. (2016) usually accept less than 20% or limbal touch. For this reason, we decided to go ahead without any changes. The limbal clearance and staining must be monitored closely and should be checked at the next follow-up visit. The edge, on the other hand, was fitting well with no signs of being too flat or too tight.

From the initial fit to the follow-up examination, the visual acuity dropped, and an over-refraction of -1.00 D improved the visual acuity back to baseline. The reason for this could be inaccurate over-refraction when fitting. The initial examination lasted a long time. A tired and unfocused patient could influence the refraction. Research found that lens settling does not affect over-refraction and visual acuity (Bray et al., 2017). Large corneal clearance will affect visual acuity (Fadel, 2019). The corneal clearance varies largely across the cornea of this patient. If the patient focused through a slightly different part of the lens on the follow-up examination, this might have affected the visual acuity. Corneal oedema is a complication of scleral lens wear that also affect over-refraction and visual acuity. Studies have failed to show clinical significant oedema following daily wear of scleral lenses in normal corneas, but sub-clinical levels of edema might occur (Fadel, 2019). The patient did not present with other signs of corneal oedema, but attention to the corneal wellbeing, and the state of the endothelium in particular (Fadel & Kramer, 2019) is important at all future follow-up examinations.

The most common reason for discontinuation of scleral lens wear is issues with lens handling (Asena & Altnörs, 2016). Educating the patient well is important, as well as patient motivation. In this case, the patient was highly motivated, as he felt blind without a lens. After recovering from the heart surgery, lens handling was no issue either. An ophthalmologist diagnosed the patient with PMD in 2013, and the findings in the anterior segment of this patient resemble characteristics of PMD. However, detailed anterior and posterior elevation maps and full pachymetry maps with thickness data would add valuable information to the state of the condition of the patient, and possible progression (Belin et al., 2011). This will be included in future follow-up of this patient. Examination of the posterior segment was not included in this case report. As glaucoma is a potential contraindication to scleral lens wear (Fadel & Kramer, 2019), future follow-up examinations should also include procedures such as dilated fundus examination, posterior segment OCT, intraocular pressure and perimetry. With the history of being lost to follow-up for several years, it is crucial to emphasize the importance of regular 6-monthly follow-up examinations to this patient.

Conclusion

A patient with PMD presented with a poorly fitting Rose K2 IC lens and was successfully refitted with a Onefit scleral lens. Lens handling was no obstacle, and the patient was happy with vision and comfort. The next follow-up visit will take place 6 months from the last examination, with specific attention to the corneal status, limbal clearance and the posterior segment.

© Copyright Lundanes, E., et al. This article is distributed under the terms of the Creative Commons Attribution License, which permits unrestricted use and redistribution provided that the original author and source are credited.

References

Asena, L., & Altnörs, D. D. (2016). Clinical outcomes of scleral lens lenses for visual rehabilitation in patients with pellucid marginal degeneration. *Contact Lens and Anterior Eye*, 39(6), 420–424. <https://doi.org/10.1016/j.clae.2016.06.010>

- Belin, M. W., Asota, I. M., Ambrosio, R., & Khachikian, S. S. (2011). What's in a name: Keratoconus, pellucid marginal degeneration, and related thinning disorders. *American Journal of Ophthalmology*, *152*(2), 157–162.e1. <https://doi.org/10.1016/j.ajo.2011.03.028>
- Biswas, S., Brahma, A., Tromans, C., & Ridgway, A. (2000). Management of pellucid marginal corneal degeneration. *Eye*, *14*, 629–634.
- Blanchard Contact Lenses. (2018). <http://blanchardlab.com/wp-content/uploads/2018/09/Onefit-Fittingguide-08-13-18-Web.pdf>
- Bray, C., Britton, S., Yeung, D., Haines, L., & Sorbara, L. (2017). Change in over-refraction after scleral lens settling on average corneas. *Ophthalmic and Physiological Optics*, *37*(4), 467–472. <https://doi.org/10.1111/opo.12380>
- Efron, N. (2018). *Contact lens practice* (Third edition.). Elsevier.
- Fadel, D. (2019). Scleral lens issues and complications related to a non-optimal fitting relationship between the lens and ocular surface. *Eye Contact Lens*, *45*(3), 152–163. <https://doi.org/10.1097/icl.0000000000000523>
- Fadel, D., & Kramer, E. (2019). Potential contraindications to scleral lens wear. *Contact Lens and Anterior Eye*, *42*(1), 92–103. <https://doi.org/10.1016/j.clae.2018.10.024>
- Jinabhai, A., Radhakrishnan, H., & O'Donnell, C. (2011). Pellucid corneal marginal degeneration: A review. *Contact Lens and Anterior Eye*, *34*(2), 56–63. <https://doi.org/10.1016/j.clae.2010.11.007>
- Koc, M., Tekin, K., Inanc, M., Kosekahya, P., & Yilmazbas, P. (2018). Crab claw pattern on corneal topography: Pellucid marginal degeneration or inferior keratoconus? *Eye (Lond)*, *32*(1), 11–18. <https://doi.org/10.1038/eye.2017.198>
- Martinez-Abad, A., & Pinero, D. P. (2019). Pellucid marginal degeneration: Detection, discrimination from other corneal ectatic disorders and progression. *Contact Lens and Anterior Eye*, *42*(4), 341–349. <https://doi.org/10.1016/j.clae.2018.11.010>
- Michaud, L., Lipson, M., Kramer, E., & Walker, M. (2019). The official guide to scleral lens terminology. *Contact Lens and Anterior Eye*. <https://doi.org/10.1016/j.clae.2019.09.006>
- Otchere, H., Jones, L. W., & Sorbara, L. (2017). Effect of time on scleral lens settling and change in corneal clearance. *Optometry and Vision Science*, *94*(9), 908–913. <https://doi.org/10.1097/oxp.0000000000001111>
- Ozek, D., Kemer, O. E., & Altıaylık, P. (2018). Visual performance of scleral lenses and their impact on quality of life in patients with irregular corneas. *Arquivos Brasileiros de Oftalmologia*, *81*(6), 475–480. <https://doi.org/10.5935/0004-2749.20180089>
- Pullum, K. W., & Buckley, R. J. (1997). A study of 530 patients referred for rigid gas permeable scleral contact lens assessment. *Cornea*, *16*(6), 612–22.
- Rathi, V. M., Dumpati, S., Mandathara, P. S., Taneja, M. M., & Sangwan, V. S. (2016). Scleral contact lenses in the management of pellucid marginal degeneration. *Contact Lens and Anterior Eye*, *39*(3), 217–220. <https://doi.org/10.1016/j.clae.2015.11.005>
- van der Worp, E. (2015). *A guide to scleral lens fitting (2 ed.)* (Report). College of Optometry, Pacific University.
- Walker, M. K., Bergmanson, J. P., Miller, W. L., Marsack, J. D., & Johnson, L. A. (2016). Complications and fitting challenges associated with scleral contact lenses: A review. *Contact Lens and Anterior Eye*, *39*(2), 88–96. <https://doi.org/10.1016/j.clae.2015.08.003>